

A CASE STUDY

Healed Hot Spot Turns Skeptic Around

By Dennis Arp
Contributing Editor

Brandy Ellis, DVM, had heard laser therapy touted as a cure-all, which only fueled her skepticism that the technological advance might be all hype and no help with her day-to-day delivery of veterinary care.

Then the clinic at which she works in Olive Branch, Miss., added a Companion Therapy Class IV laser, and she got a chance to test it. At first she and her colleague, Ruth Wilburn, DVM, used the laser to speed healing of incisions and to relieve post-operative pain. Then they found it was effective in treating back and muscle injuries.

"We got a huge response in cases that had not previously responded to conventional methods," Dr. Ellis says.

So when client Pete Caldwell brought in Buddy, his German shepherd mix, because of an acute case of lick granuloma, she had laser therapy in the back of her mind. When the hot spot didn't respond to oral and topical treatments, the laser moved front and center.

The success enjoyed in this case has helped convert Ellis and her client into laser therapy believers.

"I couldn't be happier with the way things turned out," says Caldwell, a Memphis, Tenn., resident. "For a while it looked like that hot spot would never clear up, but now Buddy's doing just great. He's a rescue, and he's been the best dog anyone could have, so any time something is wrong with him, it bothers me quite a bit."

Here is a closer look at the case and the role Class IV laser therapy played in its resolution.

PATIENT

Buddy, a 5-year-old neutered male German shepherd and husky mix with a limited previous history of problems with dermatitis.

PROBLEM

An acute case of lick granuloma one-half-inch long and three-fourths-inch wide on Buddy's right front paw.

Caldwell has been bringing Buddy to the Olive Branch Animal Clinic since 2005, but this was his first experience with a hot spot. By the time he brought the dog in last Aug. 25, he had tried applying topical treatments and a sour-tasting solution to the area in hopes of

discouraging Buddy from licking. Neither tactic was working.

Both Caldwell and Ellis struggled to come up with a cause for the lick granuloma. Buddy isn't a chronic allergy sufferer, and there didn't seem to be a behavioral factor involved.

"Of course, sometimes we don't ever find a trigger," Ellis says. "In this case, we still don't know what caused this spot."

TREATMENT PLAN AND PROCEDURE

Ellis first sought to combat the hot spot by prescribing prednisone, an oral antibiotic and Gentocin topical spray to combat infection. She broached the idea of also trying laser therapy, but Caldwell wanted to give the other treatments a chance to work.

When Caldwell and Buddy returned Sept. 4, the lesion was no better. By this time, Ellis was curious enough about the potential for laser therapy to speed healing in such a case that she offered to treat the dog at no charge. Caldwell agreed.

Buddy became the first lick granuloma case on which Ellis used the laser.

"In this case, I wanted to use it for me and the greater knowledge it would bring that we might be able to apply to future cases," she says.

Caldwell just wanted Buddy to get better.

"I'm confident in the skills of Dr. Ellis and Dr. Ruth, so once Dr. Ellis talked to me about it more, I was ready to say yes," he says.

THERAPY LASER SETTINGS

The hot spot was treated using a pre-set Contaminated Wound Protocol: 2 watts for two minutes. Ellis provided the following breakdown:

* First 30 seconds, frequency of 20 with 30 joules of energy delivered.

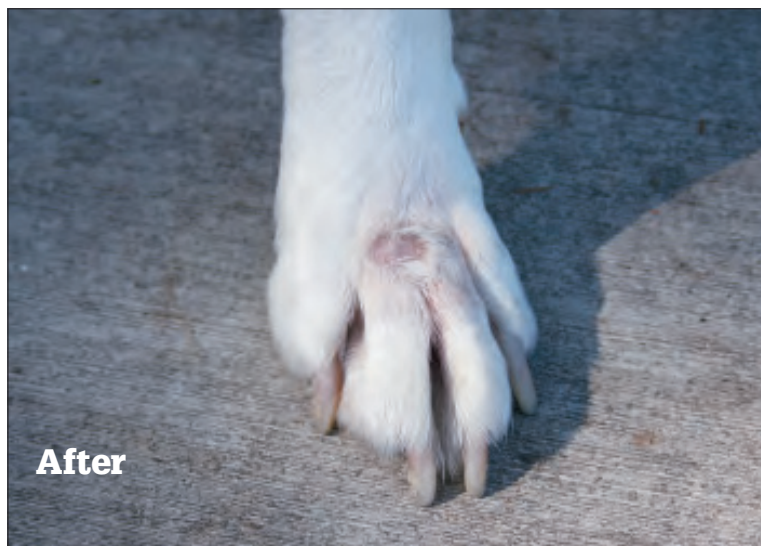
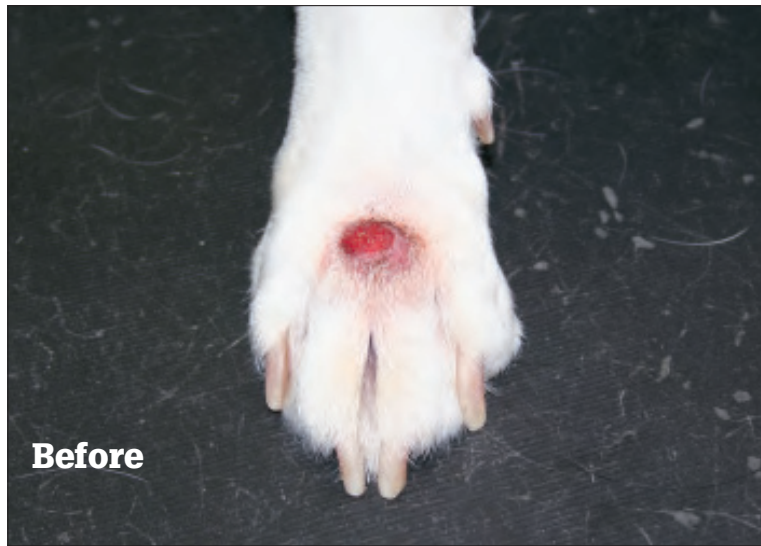* Second 30 seconds, frequency of 500 with 60 joules of energy delivered.

* Third 30 seconds, frequency of 5,000 with 90 joules of energy delivered.

* Fourth 30 seconds, frequency of 10,000 with 120 joules of energy delivered.

The Companion Therapy laser comes with programming embedded, which has helped Ellis and others at the clinic overcome any trepidation and become confident about its safe and effective use, she says.

The protocol is designed to include low



A hot spot less than an inch wide was treated using a Companion Therapy Laser and a pre-set Contaminated Wound Protocol. After a dozen treatments, the lesions on Buddy, a German shepherd mix, were gone for good.

hertz (20) for pain reduction, higher hertz (500 and 5,000) for swelling and high hertz (10,000) for antimicrobial effect.

RESULTS

Buddy's regimen called for six laser treatments over a 3½-week period, and after his first visit, "We were already noticing that the lesion was dryer, and the owner was noticing that the dog wasn't licking the area as much," Ellis says.

Before the fifth treatment, the affected area was measured at one-fourth-inch long by one-fourth-inch wide. After

the sixth treatment, both Buddy and Caldwell left happy.

The condition did recur about a month later, and six more treatments were administered. The last was Dec. 10, and so far no lesions have returned.

Since then, Ellis has found herself searching for new opportunities to apply laser therapy. She doesn't call it a cure-all, but she has a new appreciation for how it can be folded into a host of treatment plans.

Meanwhile, Caldwell is singing the praises of Drs. Ellis and Wilburn.

"I've always felt good about taking any of my three dogs to their clinic," he says. "Now I have one more reason to keep going back." ●

For a while there I thought that hot spot would never clear up, but now Buddy's doing just great.

— Pete Caldwell, a Memphis, Tenn., dog owner

This Education Series article is underwritten by LiteCure LLC of Newark, Del.